

# Diagnostic Comparison of CT Scans and Colonoscopy for Immune-Related Colitis in Ipilimumab-Treated Advanced Melanoma Patients



Marlene Garcia-Neuer<sup>1</sup>, Melina E. Marmarelis<sup>2</sup>, Sushrut R. Jangi<sup>3</sup>, Jason J. Luke<sup>5</sup>, Nageatte Ibrahim<sup>1,4,6</sup>, Meredith Davis<sup>1</sup>, Janice Weinberg<sup>7</sup>, Hilary Donahue<sup>1</sup>, Nancy Bailey<sup>1</sup>, F. Stephen Hodi<sup>1,4</sup>, Elizabeth L. Buchbinder<sup>1,4</sup>, and Patrick A. Ott<sup>1,4</sup>

## Abstract

Colitis can be a life-threatening toxicity for patients treated with immune checkpoint blockade antibodies. With the anticipated widespread use of these reagents, the timely and accurate diagnosis of immune-related colitis becomes increasingly important. To better understand the clinical presentation of colitis from ipilimumab and to assess the use of CT scans of the abdomen/pelvis as a diagnostic tool, we retrospectively analyzed patients with advanced melanoma who received ipilimumab at our institution. Ninety nine (33%) of 303 patients developed diarrhea during therapy, and 46 patients (15%) received corticosteroids for colitis. Of the patients with diarrhea, 48 (48%) underwent colo-

noscopy and 46 (46%) underwent both CT and colonoscopy. In the 34 patients (34%) with a CT and biopsy, CT was highly predictive of colitis on biopsy (positive predictive value 96%), and the absence of CT findings was predictive of a negative biopsy (negative likelihood ratio 0.2). In patients who had symptoms and CT evaluation, CT was highly predictive of the need for steroids to reach resolution of symptoms (positive predictive value 92%, positive likelihood ratio 7.3). We conclude that CT is a fast, reliable, and noninvasive mode of diagnosing colitis, whereas colonoscopy and biopsy may not be needed to establish that diagnosis. *Cancer Immunol Res*; 5(4): 286–91. ©2017 AACR.

## Introduction

Immune checkpoint blockade, using mAbs to cytotoxic lymphocyte antigen 4 (CTLA-4) and programmed death 1 (PD-1) receptors have emerged as effective treatment strategies in solid and hematologic malignancies (1). CTLA-4 and PD-1/PD-L1 are negative regulators of T cell-mediated immune responses, and their blockade leads to an increase in T-cell activation and infiltration of tumors. In metastatic melanoma, an mAb to CTLA-4 (ipilimumab) was the first drug that demonstrated improved overall survival in a randomized study, and it has also shown durable objective responses (2–4). The mAbs to PD-1, pembrolizumab and nivolumab, have also shown survival benefit in phase III studies in metastatic melanoma (1). The combination of nivolumab and ipilimumab results in longer progression-free survival and higher rates of response compared with ipilimumab

(and numerically to nivolumab), leading to FDA approval and increased use of combination therapy with ipilimumab and nivolumab (5, 6). With increased use of these therapies in a wide spectrum of cancers, timely and accurate diagnosis of serious and life-threatening immune-related adverse events (irAE) becomes critical.

Gastrointestinal irAEs and immune-related colitis can occur at any time during or after treatment, with 30% to 35% of patients experiencing mild symptoms and 5% to 8% experiencing moderate to severe symptoms (3, 7). Differentiating between patients with mild symptoms and those who will progress to severe and life-threatening colitis is difficult, especially because presentation can be subtle and easily confused with an infectious etiology. Given the life-threatening nature of ipilimumab-induced colitis and the favorable response to steroids if started early, urgent and accurate diagnosis is essential (8, 9).

Colonoscopy, including biopsy of colonic mucosa, is currently the only validated diagnostic tool to confirm immune-related colitis, but physicians are using less invasive methods, such as CT scans, as a proxy for colonoscopy (10, 11). Intestinal perforation is a rare, but serious, complication of colonoscopy; patients with inflamed colonic tissues, as occurs in immune-related colitis, are at increased risk (3, 12, 13). Therefore, accurately diagnosing immune-related colitis through noninvasive measures, such as CT scans, would decrease exposure to the potential complications of colonoscopy. Radiologic assessment has not been previously correlated with assessment by colonoscopy and biopsy of colonic mucosa to establish a diagnosis of colitis induced by immune checkpoint inhibition; however, combined PET/CT studies in patients with inflammatory bowel disease support CT correlation

<sup>1</sup>Department of Medical Oncology Dana Farber Cancer Institute, Boston, Massachusetts. <sup>2</sup>Department of Medical Oncology, University of Pennsylvania, Philadelphia, Pennsylvania. <sup>3</sup>Department of Medicine, Division of Gastroenterology, Brigham and Women's Hospital, Boston, Massachusetts. <sup>4</sup>Harvard Medical School, Boston, Massachusetts. <sup>5</sup>Department of Medicine, Section of Hematology/Oncology, University of Chicago, Chicago, Illinois. <sup>6</sup>Current affiliation: Merck; Merck & Co., Inc., Kenilworth, NJ, USA. <sup>7</sup>Department of Biostatistics, Boston University, Boston, Massachusetts.

**Corresponding Author:** Patrick A. Ott, Dana Farber Cancer Institute, 450 Brookline Avenue, Boston, MA 02215. Phone: 617-582-9030; Fax: 617-632-6727; E-mail: patrick\_ott@dfci.harvard.edu

doi: 10.1158/2326-6066.CIR-16-0302

©2017 American Association for Cancer Research.

of colitis with endoscopic findings (14, 15). Validating the effectiveness of CT scans for diagnosing ipilimumab-induced colitis may decrease time to diagnosis and reduce the risk of bowel perforation associated with colonoscopy. It would also allow clinicians to more easily separate patients with mild gastrointestinal symptoms that will resolve on their own from those that may require steroids for resolution of immune-related colitis.

## Materials and Methods

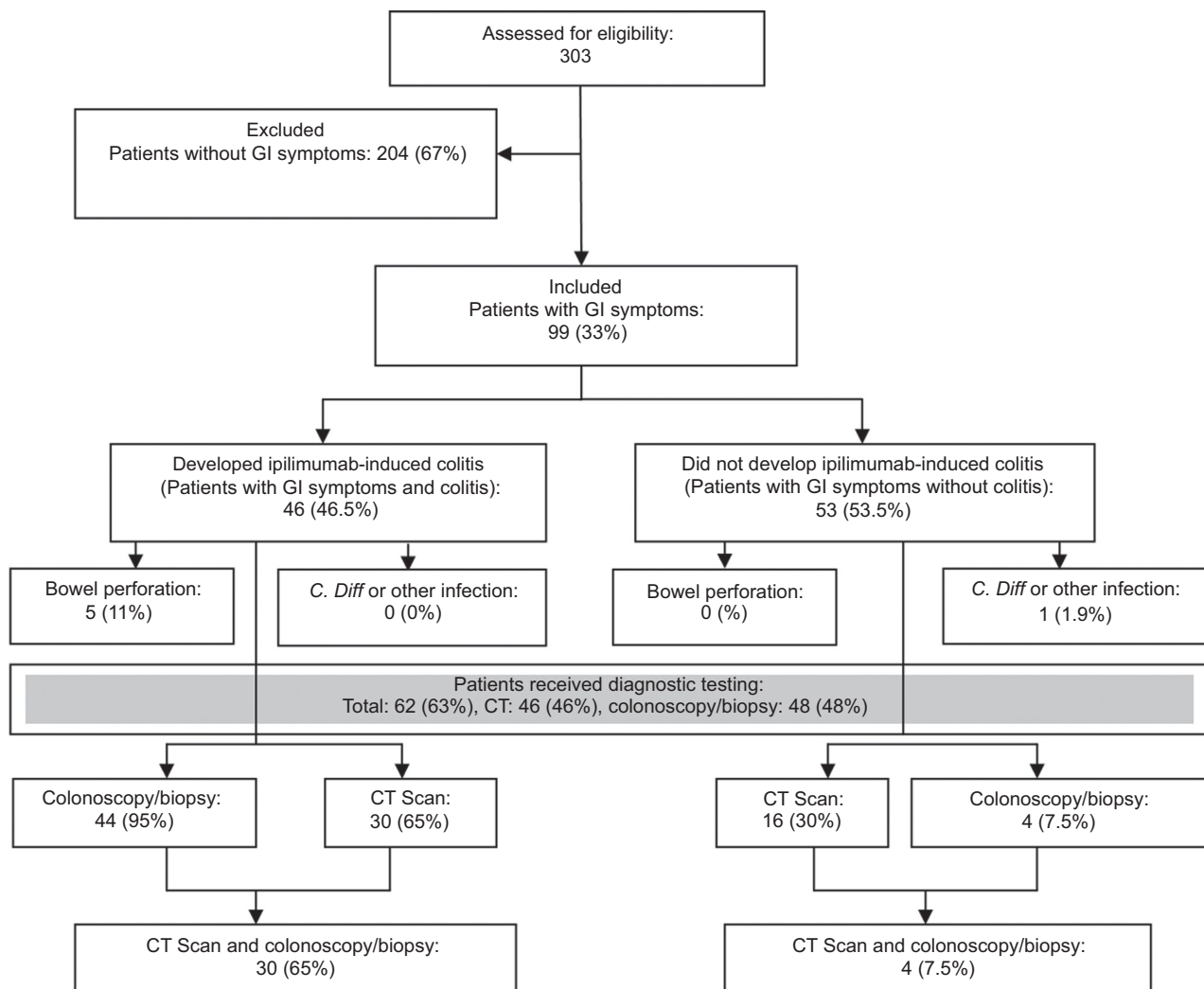
### Study design and patient population

This retrospective cohort study was conducted at the Dana-Farber Cancer Institute (Boston, MA). To be included in the study, patients needed a diagnosis of metastatic melanoma, had received at least one dose of ipilimumab between 2008 and 2015, and had at least one episode of diarrhea during ipilimumab treatment (Fig. 1). Patients were considered to have immune-related colitis if they had biopsy-proven colitis that was not of an infectious

etiology or required steroids for the resolution of their gastrointestinal symptoms. The study was approved by the Dana-Farber/Harvard Cancer Center Institutional Review Board. We performed a chart review of the electronic medical records to identify patient information, including diagnostic and demographic data.

### Statistical analysis

The primary goal of the study was to identify characteristics [age, sex, body mass index (BMI), lactase dehydrogenase (LDH), dosage, or timing and resolution of symptoms] that were different between the group of patients who only had gastrointestinal symptoms compared with the group of patients who developed immune-related colitis. To test statistical differences between the two groups, a two-sided Welch *t* test with a 95% confidence interval was used for the continuous variables, and a  $\chi^2$  test was used for the categorical variables. To test for gender differences, a  $\chi^2$  test with Yates correction was used because of the small sample size of



**Figure 1.**

Representation of the prevalence of gastrointestinal symptoms, steroid treatment, and bowel perforation in both the confirmed colitis and gastrointestinal symptoms groups as well as in the total cohort. Prevalence of CT and colonoscopy diagnostic exams is also shown in both groups and in the total cohort. GI, gastrointestinal, *C. Diff*, *Clostridium difficile*.

females. The mean and SD for each variable and the number and the percent for each categorical variable were calculated and reported. The secondary goal was to assess the sensitivity, specificity, positive and negative predictive value, and positive and negative likelihood ratios of the CT scans compared with the "gold standard" of colonoscopy with biopsy. Two methods were used to identify the validity of the CT scan results. First, for patients who received both a CT and colonoscopy/biopsy, the biopsy results were used to validate the CT findings. For patients who received a CT and no colonoscopy/biopsy, the CT findings were validated by their need to receive steroid treatment for resolution of symptoms. Patients were confirmed as having immune-related colitis if they had a biopsy documenting immune-related pathogenesis or needed steroid treatment to manage their symptoms. The analysis was performed in R, statistical program.

**Results**

**Diagnostic workup of patients who developed diarrhea after ipilimumab**

Of the 303 patients who received ipilimumab, 99 patients (33%) developed diarrhea. In 46 of these 99 patients, the diarrhea was attributed to immune-related colitis. Forty three of these 46 patients (93.5%) required corticosteroids for resolution of symptoms (Fig. 1). Sixty two of the 99 patients who reported gastrointestinal symptoms (63%) had further workup with 34 patients (34%) receiving both a colonoscopy with biopsy and a CT scan. The CT scan alone was used in 46 patients (46%), and colonoscopy with biopsy was used in 48 patients (48%; Fig. 1). Common abdomen/pelvis CT findings included bowel wall thickening (57%) and air/fluid levels secondary to diarrhea (23%). Only 3% of the patients who were diagnosed with colitis did not have defined findings on their CT scans.

**Characteristics of patients with gastrointestinal symptoms with and without immune-related colitis**

We compared patients with gastrointestinal symptoms who were diagnosed with immune-related colitis with those who did not have colitis (Table 1). Patients with immune-related colitis were older compared with patients with gastrointestinal symptoms without colitis. They also had received more ipilimumab doses, and had a shorter interval between doses, than patients with gastrointestinal symptoms alone. BMI, LDH, and time of onset of symptoms were similar between the two groups. However, patients with immune-related colitis had significantly longer time to resolution of symptoms than patients with gastrointestinal symptoms only. Fourteen patients required infliximab for resolution of symptoms. Colitis recurred in 5 patients after infliximab, with one patient requiring three doses. No patient with colitis had a concurrent infection with *Clostridium difficile* or other pathogenic microbes.

Bowel perforation occurred in 5 of 303 patients (1.7%) treated with ipilimumab in our cohort. Patients with bowel perforation were significantly older (72.8, ± 5.45, n = 5) compared with patients with colitis not resulting in bowel perforation (64.2 ± 13.61, n = 46; P = 0.012).

**Confirmation of CT scans as diagnostic tool for ipilimumab-induced colitis**

The diagnostic utility of the CT scan was confirmed using two methods. First, radiologic findings on CT scan suggestive of colitis

**Table 1.** Characteristics of patients with colitis versus self-limited diarrhea

	<b>Ipilimumab-induced colitis Mean (SD)</b>	<b>Gastrointestinal symptoms Mean (SD)</b>	
Subgroup			Total
N	46	53	99
Gender, n (%)			P
Male	31 (67.4%)	34 (63%)	
Female	15 (32.6%)	20 (37%)	
			0.64
Age	65.3 (±13.8)	58.13 (±13.4)	<b>0.01</b>
BMI	28.4 (±4.9)	29.1 (±5.9)	0.51
LDH	236.8 (±203)	290 (±255)	0.25
Number of doses before onset of symptoms	3 (±1.3)	2.5 (±1.2)	<b>0.052</b>
Days to onset of symptoms	53.6 (±35)	72.8 (±79)	0.13
Days to resolution of symptoms	38.3 (±29)	6.3 (±7.9)	<b>1.23 × 10<sup>-8</sup></b>
Days per dose of ipilimumab (dose density)	17.9 (± 9.0)	24.7 (±21.2)	<b>0.04</b>

NOTE: Of the 99 patients who developed gastrointestinal symptoms after receiving ipilimumab, 46 patients were diagnosed with immune-related colitis. The demographic and clinical characteristics between the two patient groups (colitis vs. diarrhea not attributed to colitis) are outlined. Bold: significant P values (< 0.05)

(e.g., bowel wall thickening, air/fluid levels, mesenteric stranding) were correlated with histologic results of colonic mucosal biopsies (the most definitive test for the diagnosis of colitis) in the group of 34 patients who had both colonoscopy/biopsy and a CT scan for evaluation (Table 2: combination CT/biopsy group). Second, radiologic findings on CT scan were correlated with effective use of corticosteroids for the resolution of gastrointestinal symptoms (strongly suggesting immune-related colitis) in the group of 43 patients who needed steroids for resolution of their diarrhea [all of whom underwent CT, but only a subset had colonoscopy/biopsy (CT/corticosteroid group)]. In the CT/biopsy group, the sensitivity and specificity of CT to detect colitis was 85% and 75%, respectively. The positive and negative predictive value of the CT was 95.8% and 42.9%, respectively. In the CT/corticosteroid group, the sensitivity and specificity of CT was of 76.7% and 88.2%, respectively. The positive and negative predictive value of the CT was 92% and 68.2%, respectively.

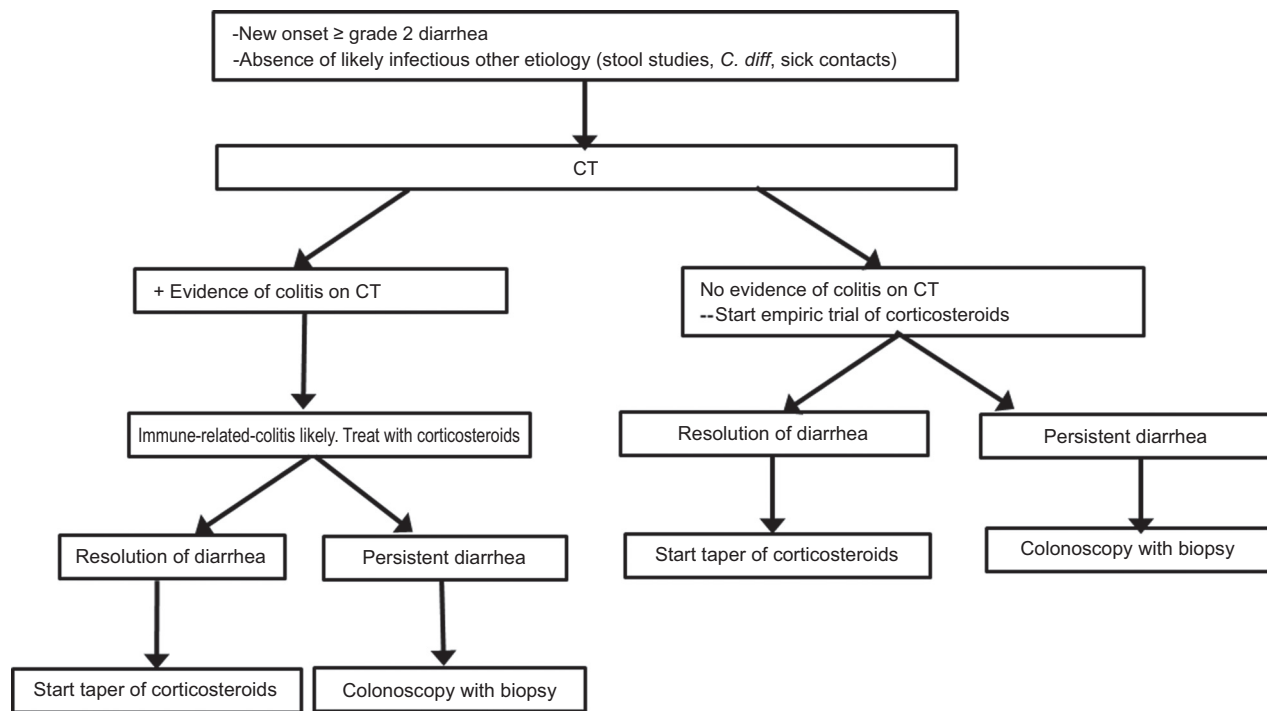
**Radiographic, endoscopic, and histologic characteristics of ipilimumab-induced colitis**

Diffuse pan-colitis with circumferential wall thickening was a frequent radiographic finding, although segmental colitis with

**Table 2.** Sensitivity and specificity analysis of CT scans

	<b>CT/biopsy</b>	<b>CT/corticosteroid</b>
Subgroup		
n	34	47
Sensitivity	85.2%	76.7%
Specificity	75.0%	88.2%
PPV	95.8%	92.0%
NPV	42.9%	68.2%
Positive likelihood ratio (LR+)	3.3	6.5
Negative likelihood ratio (LR-)	0.19	0.26

NOTE: Analysis of CT scan data in two groups. Biopsy group validated CT findings with colonoscopy and biopsy results from patients. Steroid treatment group validated CT findings with the need for patients to receive steroid treatment for resolution of ipilimumab-induced colitis symptoms.



**Figure 2.**

The proposed workup of patients presenting with gastrointestinal symptoms who are being treated with checkpoint inhibitors. Ir-colitis, immune-related colitis; C. Diff, *Clostridium difficile*.

specific involvement of ascending, descending, or sigmoid was also seen. Atypical radiographic presentations of colitis included diffuse colonic dilation rather than bowel wall thickening. Endoscopic findings were also variable: They ranged from severe inflammation characterized by deeply ulcerated, congested, and erythematous mucosa in a continuous and circumferential pattern to mild, segmental involvement. Histologically, similar variability was noted, including ulcerated mucosa with crypt apoptosis and nonnecrotizing granulomas, to mild, active focal colitis.

In the majority of cases, the radiographic, endoscopic, and histologic diagnoses were consistent. However, in a few cases, radiologic findings were not consistent with endoscopic and pathologic diagnoses: A 44-year-old male with immune-related colitis had a CT with no evidence for colitis; however, endoscopy revealed a diffuse area of moderately erythematous mucosa in the rectosigmoid colon whose pathology showed a moderate active colitis, focal crypt apoptosis, and nonnecrotizing granulomas. In a 95-year-old female, CT findings were suggestive of only a mild colitis; however, colonoscopy revealed a severe colitis with sigmoid ulcerations, with pathology showing moderate colitis. Endoscopic diagnosis also did not necessarily coincide with pathologic diagnosis; in a 69-year-old male with immune-related colitis, a flexible sigmoidoscopy revealed a normal appearing colonic mucosa, whereas the pathology supported focal active colitis with a CT suggestive of wall thickening and mild inflammatory changes in the sigmoid colon.

## Discussion

Immune-related-colitis can be a life-threatening irAE for patients treated with immune checkpoint inhibitors. With the

increased use of these agents, particularly the combination of anti-CTLA-4 and PD-1 pathway inhibition in melanoma and other cancers, timely and accurate diagnosis of colitis will become increasingly important for oncologists. With this analysis, we hope to help clinicians distinguish ipilimumab-induced colitis from self-limited gastrointestinal symptoms in a timely and noninvasive manner. To this end, we identified several characteristics that were associated with a greater likelihood of immune-related colitis compared with self-limited gastrointestinal symptoms and created an algorithm for workup of patients presenting with gastrointestinal symptoms (Fig. 2). Advanced age, higher number of doses of ipilimumab, and shorter intervals per dose (greater dose density) were found to be associated with immune-related colitis in the 99 patients who had diarrhea and other gastrointestinal symptoms after treatment with ipilimumab. The frequencies of diarrhea and colitis in our cohort were similar to those reported in the literature and between the patients treated on expanded access protocol and as standard of care in our cohort (3, 7, 8, 11). Bowel perforation was higher in patients with advanced age. The increased risk of immune-related colitis and bowel perforation in older patients may be mediated by immune deregulation and an increased inflammatory response in the aging gut (16–18). Of note, in a randomized phase II study, severe gastrointestinal toxicities, including colitis, were found to be significantly less frequent when patients with advanced melanoma were treated with ipilimumab in combination with granulocyte macrophage colony-stimulating factor (GM-CSF) compared with ipilimumab alone (18). In preclinical models, the promotion of T regulatory cells in the gut mucosa was found to be dependent on CD103<sup>+</sup> mesenteric lymph node dendritic cells

(DC); generation of these DCs requires GM-CSF (19). Furthermore GM-CSF<sup>-/-</sup> mice develop severe colitis that is prevented with the administration of GM-CSF, highlighting its role in mucosal repair (20, 21).

Patients in our cohort with diarrhea and associated symptoms not attributed to immune related colitis had a significantly shorter course of diarrhea compared with those who developed colitis. In addition, a higher number of ipilimumab doses was associated with a greater likelihood of gastrointestinal symptoms requiring corticosteroid treatment for resolution. The clinical course of gastrointestinal symptoms may help identifying patients who are at greater risk of developing colitis requiring steroids for resolution. Concurrently, new insights into the microbiome could be used to stratify patients. The aging gut has both physiologic and microbial differences, which may contribute to increased inflammation and immune deregulation (16, 17). Some evidence suggests that the microbiome influences both allograft rejection and the efficacy of immunotherapy and therefore mediates a modulatory effect on immunotherapy toxicity (22–24). A prospective cohort study analyzing inflammatory markers, such as calprotectin, lactoferrin, M2-PK, and S100A12, as well as a microbiome panel analysis of patients who have gastrointestinal symptoms and those who develop immune-related colitis, would be useful in understanding the biological mechanisms of inflammation and the microbiome in immune-related colitis (17, 25).

We confirm CT as an accurate and noninvasive diagnostic tool to distinguish immune-related colitis from self-limited diarrhea. In patients who received ipilimumab and developed gastrointestinal symptoms, a CT with evidence of colitis had a 96% positive predictive value (PPV) of correctly diagnosing immune-related colitis using colonoscopy with biopsy as the benchmark for the diagnosis of colitis. The absence of CT findings suggestive of colitis in these patients had a negative predictive value (NPV) of 43%. Therefore, a CT scan is a suitable diagnostic tool to make a diagnosis of immune-related colitis, but cannot reliably rule out the diagnosis. It is notable though that PPV and NPV were 92% and 68%, respectively, when the presence or absence of CT findings suggesting colitis was measured against the need for treatment to resolve symptoms as a benchmark for the presence of colitis (rather than the histologic diagnosis), suggesting a higher NPV when using this clinically arguably more relevant measure of colitis. Although a spectrum of clinical findings was noted in immune-related colitis, the radiographic, endoscopic, and histologic findings were generally consistent. However, if the clinical suspicion for colitis is high and CT findings do not indicate colitis, the patient should be empirically treated with corticosteroid and/or a colonoscopy with biopsy be pursued.

A subset of patients did not receive either of the diagnostic tests (CT or colonoscopy with biopsy) based on clinician discretion in our retrospective study. It is conceivable that patients who did receive both tests may represent a population with more severe symptoms and thus skew the data toward favoring the accuracy of a CT scan. However, because we

assessed all patients who developed gastrointestinal symptoms, we likely also captured all the less severe cases in our analysis. In addition, patients with most severe symptoms/highest grade colitis are the patients who would benefit the most from a rapid and accurate diagnosis without the need for colonoscopy to start appropriate treatment expeditiously and avoid the risks of a colonoscopy if possible.

Given the increased use of PD-1 pathway-directed therapy and the anticipated use of combined PD-1/PD-L1 and CTLA-4 inhibition in melanoma and other cancers, prospective studies validating our retrospective analysis of CT diagnosis of immune-related colitis are warranted in patients treated with these agents. However, as immune-related colitis induced by PD-1/PD-L1 inhibitors and combined CTLA-4/PD-1 inhibition presents clinically in much the same way as ipilimumab-induced colitis (suggesting similar etiology and pathogenesis), it appears reasonable to extrapolate the findings from our study to other checkpoint inhibitors and checkpoint inhibitor combinations while prospective data are lacking.

In conclusion, this retrospective analysis indicates that CT of the abdomen/pelvis may be a fast, accurate, and noninvasive mode of diagnosing ipilimumab-induced immune-related colitis and colonoscopy with biopsy may not be needed to firmly establish that diagnosis.

#### Disclosure of Potential Conflicts of Interest

J.J. Luke reports receiving other commercial research support from Bristol-Myers Squibb and is a consultant/advisory board member for Amgen, Bristol-Myers Squibb, CheckMate, and Merck. J. Weinberg is a statistical editor for *Journal of the American Heart Association*. F.S. Hodi reports receiving a commercial research grant from Bristol-Myers Squibb (to institution), is a consultant/advisory board member for Bristol-Myers Squibb, and has provided expert testimony for a patent pending intellectual property per institutional policy on MICA-related disorders. P.A. Ott is a consultant/advisory board member for Alexion, Bristol-Myers Squibb, Celldex, CytomX, Neon Therapeutics, Pfizer, and Roche/Genentech. No potential conflicts of interest were disclosed by the other authors.

#### Authors' Contributions

**Conception and design:** M. Garcia-Neuer, M.E. Marmarelis, P.A. Ott  
**Development of methodology:** M. Garcia-Neuer, M.E. Marmarelis, J.J. Luke, F.S. Hodi, P.A. Ott  
**Acquisition of data (provided animals, acquired and managed patients, provided facilities, etc.):** M. Garcia-Neuer, M.E. Marmarelis, J.J. Luke, N. Ibrahim, M. Davis, H. Donahue, F.S. Hodi, E.L. Buchbinder, P.A. Ott  
**Analysis and interpretation of data (e.g., statistical analysis, biostatistics, computational analysis):** M. Garcia-Neuer, M.E. Marmarelis, J.J. Luke, N. Ibrahim, J. Weinberg, F.S. Hodi, E.L. Buchbinder, P.A. Ott  
**Writing, review, and/or revision of the manuscript:** M. Garcia-Neuer, M.E. Marmarelis, S.R. Jangi, J.J. Luke, N. Ibrahim, M. Davis, J. Weinberg, F.S. Hodi, E.L. Buchbinder, P.A. Ott  
**Administrative, technical, or material support (i.e., reporting or organizing data, constructing databases):** M. Garcia-Neuer, M.E. Marmarelis, N. Bailey, P.A. Ott  
**Study supervision:** M. Garcia-Neuer, P.A. Ott

Received October 31, 2016; revised December 5, 2016; accepted February 20, 2017; published online April 3, 2017.

#### References

- Sharma P, Allison JP. The future of immune checkpoint therapy. *Science* 2015;348:56–61.
- Schadendorf D, Hodi FS, Robert C, Weber JS, Margolin K, Hamid O, et al. Pooled analysis of long-term survival data from phase II and phase III trials

- of ipilimumab in unresectable or metastatic melanoma. *J Clin Oncol* 2015;33:1889–94.
3. Hodi FS, Harris A, Johnson DW, Kesselhut J, Li JJ, Luxton G, et al. Improved survival with ipilimumab in patients with metastatic melanoma. *N Engl J Med* 2010;363:609–19.
  4. Robert C, Thomas L, Bondarenko I, O'Day S, M D JW, Garbe C, et al. Ipilimumab plus dacarbazine for previously untreated metastatic melanoma. *N Engl J Med* 2011;364:2517–26.
  5. Postow MA, Chesney J, Pavlick AC, Robert C, Grossmann K, McDermott D, et al. Nivolumab and ipilimumab versus ipilimumab in untreated melanoma. *N Engl J Med* 2015;372:2006–17.
  6. Larkin J, Chiarion-Sileni V, Gonzalez R, Grob JJ, Cowey CL, Lao CD, et al. Combined nivolumab and ipilimumab or monotherapy in untreated melanoma. *N Engl J Med* 2015;373:23–34.
  7. O'Day SJ, Maio M, Chiarion-Sileni V, Gajewski TF, Pehamberger H, Bondarenko IN, et al. Efficacy and safety of ipilimumab monotherapy in patients with pretreated advanced melanoma: a multicenter single-arm phase II study. *Ann Oncol* 2010;21:1712–7.
  8. Fecher LA, Agarwala SS, Hodi FS, Weber JS. Ipilimumab and its toxicities: a multidisciplinary approach. *Oncologist* 2013;18:733–43.
  9. Cheng R, Cooper A, Kench J, Watson G, Bye W, McNeil C, et al. Ipilimumab-induced toxicities and the gastroenterologist. *J Gastroenterol Hepatol* 2015;30:657–66.
  10. Weber JS, Kähler KC, Hauschild A. Management of immune-related adverse events and kinetics of response with ipilimumab. *J Clin Oncol* 2012;30:2691–7.
  11. Kim KW, Ramaiya NH, Krajewski KM, Shinagare AB, Howard SA, Jagannathan JP, et al. Ipilimumab-associated colitis: CT findings. *AJR Am J Roentgenol* 2013;200:W468–74.
  12. Arora G, Mannalithara A, Singh G, Gerson LB, Triadafilopoulos G. Risk of perforation from a colonoscopy in adults: a large population-based study. *Gastrointest Endosc* 2009;69:654–64.
  13. Beck KE, Blansfield JA, Tran KQ, Feldman AL, Hughes MS, Royal RE, et al. Enterocolitis in patients with cancer after antibody blockade of cytotoxic T-lymphocyte-associated antigen 4. *J Clin Oncol* 2006;24:2283–9.
  14. Berman D, Parker SM, Siegel J, Chasalow SD, Weber J, Galbraith S, et al. Blockade of cytotoxic T-lymphocyte antigen-4 by ipilimumab results in dysregulation of gastrointestinal immunity in patients with advanced melanoma. *Cancer Immunol* 2010;10:11.
  15. Louis E, Ancion G, Colard A, Spote V, Belaiche J, Hustinx R. Noninvasive assessment of Crohn's disease intestinal lesions with (18)F-FDG PET/CT. *J Nucl Med* 2007;48:1053–9.
  16. Biagi E, Nylund L, Candela M, Ostan R, Bucci L, Pini E, et al. Through ageing, and beyond: gut microbiota and inflammatory status in seniors and centenarians. *PLoS One* 2010;5:e10667.
  17. Morley JE. The aging gut: physiology. *Clin Geriatr Med* 2007;23:757–67.
  18. Stephen Hodi F, Lee S, McDermott DF, Rao UN, Butterfield LH, Tarhini AA, et al. Sargramostim plus ipilimumab vs ipilimumab alone for treatment of metastatic melanoma: a randomized clinical trial. *JAMA* 2014;312:1744–53.
  19. Coombes JL, Siddiqui KRR, Rancibia-Cárcamo CV, Hall J, Sun C-M, Belkaid Y, et al. A functionally specialized population of mucosal CD103+ DCs induces Foxp3+ regulatory T cells via a TGF-beta and retinoic acid-dependent mechanism. *J Exp Med* 2007;204:1757–64.
  20. Egea L, Hirata Y, Kagnoff MF. GM-CSF: a role in immune and inflammatory reactions in the intestine. *Expert Rev Gastroenterol Hepatol* 2010;4:723–31.
  21. Xu Y, Hunt NH, Bao S. The role of granulocyte macrophage-colony-stimulating factor in acute intestinal inflammation. *Cell Res* 2008;18:1220–9.
  22. Vétizou M, Pitt JM, Daillère R, Lepage P, Waldschmitt N, Flament C, et al. Anticancer immunotherapy by CTLA-4 blockade relies on the gut microbiota. *Cell* 2015;162:157–73.
  23. Sivan A, Corrales L, Hubert N, Williams JB, Aquino-Michaels K, Earley ZM, et al. Commensal *Bifidobacterium* promotes antitumor immunity and facilitates anti-PD-L1 efficacy. *Science* 2015;350:1084–9.
  24. Lei YM, Chen L, Wang Y, Stefka AT, Molinero LL, Theriault B, et al. The composition of the microbiota modulates allograft rejection. *J Clin Invest* 2016;126:2736–44.
  25. Dubin K, Callahan MK, Ren B, Khanin R, Viale A, Ling L, et al. Intestinal microbiome analyses identify melanoma patients at risk for checkpoint-blockade-induced colitis. *Nat Commun* 2016;7:10391.

# Cancer Immunology Research

## Diagnostic Comparison of CT Scans and Colonoscopy for Immune-Related Colitis in Ipilimumab-Treated Advanced Melanoma Patients

Marlene Garcia-Neuer, Melina E. Marmarelis, Sushrut R. Jangi, et al.

*Cancer Immunol Res* 2017;5:286-291.

**Updated version** Access the most recent version of this article at:  
<http://cancerimmunolres.aacrjournals.org/content/5/4/286>

**Cited articles** This article cites 25 articles, 9 of which you can access for free at:  
<http://cancerimmunolres.aacrjournals.org/content/5/4/286.full#ref-list-1>

**Citing articles** This article has been cited by 3 HighWire-hosted articles. Access the articles at:  
<http://cancerimmunolres.aacrjournals.org/content/5/4/286.full#related-urls>

**E-mail alerts** [Sign up to receive free email-alerts](#) related to this article or journal.

**Reprints and Subscriptions** To order reprints of this article or to subscribe to the journal, contact the AACR Publications Department at [pubs@aacr.org](mailto:pubs@aacr.org).

**Permissions** To request permission to re-use all or part of this article, use this link  
<http://cancerimmunolres.aacrjournals.org/content/5/4/286>.  
Click on "Request Permissions" which will take you to the Copyright Clearance Center's (CCC) Rightslink site.