

Eosinophilic Fasciitis and Acute Encephalopathy Toxicity from Pembrolizumab Treatment of a Patient with Metastatic Melanoma

Leila Khoja, Catherine Maurice, MaryAnne Chappell, Leslie MacMillan, Ayman S. Al-Habeeb, Nada Al-Faraidy, Marcus O. Butler, Patrik Rogalla, Warren Mason, Anthony M. Joshua, and David Hogg

Abstract

Anti-PD-1 inhibitors have significant activity in metastatic melanoma. Responses often occur early and may be sustained. The optimal duration of treatment with these agents is unknown. Here, we report the case of a 51-year-old woman treated with pembrolizumab, as part of the Keynote-001 trial, as first-line treatment for metastatic disease. She experienced a complete response after 13.8 months of treatment with no adverse events. One month after the last drug infusion and 18 months from starting treatment, the patient presented with eosinophilic fasciitis. She then developed acute confusion and weakness,

thought to be due to intracranial vasculitis. High-dose steroids were initiated with resolution of the fasciitis. Aspirin was commenced for presumed vasculitis with resolution of the neurologic symptoms. To our knowledge, there are no previous reports of eosinophilic fasciitis or cerebral vasculitis due to anti-PD-1 agents. This case demonstrates that toxicity may occur in association with pembrolizumab treatment after a prolonged period of treatment without toxicity. Future trials should explore the optimal duration of treatment with pembrolizumab. *Cancer Immunol Res*; 4(3); 175–8. ©2016 AACR.

Background

Checkpoint inhibitors have significantly improved survival outcomes in metastatic melanoma. Ipilimumab was FDA approved in 2010 and has shown durable responses beyond 3 years in a subset of patients (1). More recently, the PD-1 antibodies pembrolizumab and nivolumab were both approved for treatment-refractory metastatic melanoma after ipilimumab failure (2–5). Emerging data from the Keynote-006 comparative study of ipilimumab (a CTLA-4 inhibitor) and pembrolizumab have shown superiority of first-line pembrolizumab in response rates and survival (5). However, the optimal duration of treatment with anti-PD-1 agents is unknown. The majority of toxicities, particularly immune-related adverse events (irAE), appear to occur in the first 6 months of treatment, but toxicity may occur later with ongoing therapy (6).

Here, we report the case of a 51-year-old woman with M1c metastatic melanoma whom we treated with pembrolizumab as first-line treatment for metastatic disease. This patient had a complete radiologic response to pembrolizumab with no adverse events during 18 months of treatment. One month after discontinuation of treatment, she presented with eosinophilic fasciitis and went on to develop acute confusion presumed to be due to cerebral vasculitis.

Princess Margaret Cancer Centre, Toronto, Ontario, Canada.

Corresponding Author: David Hogg, Princess Margaret Cancer Centre, 610 University Avenue, Toronto, Ontario M5G 2M9, Canada. Phone: 001-416-946-4521; Fax: 001-416-946-6546; E-mail: david.hogg@uhn.ca

doi: 10.1158/2326-6066.CIR-15-0186

©2016 American Association for Cancer Research.

Case Presentation

A 51-year-old woman presented with a right calf mass. She had a background of hypertension, eczema, and depression. She had smoked one and a half packs of cigarettes per day for 30 years. Initial biopsy was suggestive of a clear cell sarcoma, and she received neoadjuvant radiotherapy (50 Gy in 25 fractions) to be followed by surgery. Preoperative review of the initial biopsy revealed S100, microphthalmia-associated transcription factor and vimentin positivity, human melanoma black antigen (HMB45) and melanoma antigen recognized by T cells (MART-1) negativity by immunohistochemistry. Molecular analysis was negative for known diagnostic chromosomal translocations consistent with a sarcoma. The lesion was determined to be a primary melanoma, and she proceeded with surgical excision and sentinel lymph node biopsy (SLN).

The mass was completely excised, and final pathology showed a primary melanoma measuring $4.5 \times 2.8 \times 2.2$ (involving the neurovascular bundle), with a mitotic rate of 2 per 10 high-power fields, no lymphovascular invasion, and a negative SLN (0/1). The tumor was BRAF negative. Preoperative radiologic staging had shown a number of nonspecific lung nodules, one of which, in the left upper lobe, showed growth during active radiologic surveillance postoperatively. This lesion measured 1 cm, and a wedge resection of the lung was performed in a second surgery. Pathology showed completely excised metastatic melanoma, and the patient continued active surveillance.

A mass in the right lower lobe was noted 15 months after lung surgery along with other multiple lung nodules, and biopsy results were consistent with metastatic melanoma. The patient was enrolled onto the Keynote-001 phase 1 trial of pembrolizumab and assigned to the treatment-naïve cohort on a 10-mg/kg every-2-week schedule. Her treatment proceeded uneventfully

Khoja et al.

with no drug-related toxicities. Her response was early, with an 84% reduction by immune-related response criteria on the first assessment scan at 2.8 months (after 6 infusions). A complete response (CR) was achieved after 13.8 months of treatment or 27 infusions. Treatment was later discontinued (after a total of 36 infusions) as a CR had been achieved and maintained (allowed on the Keynote-001 protocol).

A month after treatment was discontinued, the patient complained of muscle aches and heaviness in the limbs that were generalized and fluctuated in severity to become painful at times. Episodes were self-limiting and lasted minutes. There was no functional deficit at that time, and creatinine kinase concentrations and other elements of the blood screen—including electrolytes, hormone profile (thyroid function, adrenocorticotropic hormone, cortisol), full blood count, and liver screen—were normal. The symptoms progressed over the next 6 weeks so that she went on to report headaches accompanied by floaters in her visual fields. No deficits were found on neurologic examination, although she moved with apparent difficulty. Blood tests (normal ranges given in parentheses) showed an erythrocyte sedimentation rate (ESR) of 20 (0–20), a creatinine kinase (CK) level of 28 (0–149), and an eosinophil count of 1.8 ($0.04\text{--}0.4 \times 10^9/l$); MRI of the brain was normal. Twelve weeks after discontinuation of treatment, she had visible puffiness of the face and thickened and tethered waxy skin on all limbs and on the abdomen. No rash was evident, and muscle power was normal. The muscles were not tender, but she described them as painful and heavy or stiff. A further increase in eosinophil count to 5.24 at that time prompted a clinical diagnosis of eosinophilic fasciitis. An MRI of the right upper limb revealed marked fascial edema associated with the musculature of the arm and the right chest wall involving the latissimus dorsi, serratus anterior, and pectoralis muscles (Fig. 1). A full-thickness biopsy of skin and subcutaneous tissue performed 2 weeks later showed infiltration of the dermis with a lympho-eosinophilic infiltrate with scattered eosinophils in the interstitium.

The fascia contained a denser infiltrate of eosinophils, plasma cells, and lymphocytes, findings consistent with a diagnosis of eosinophilic fasciitis (Fig. 1).

Just prior to the muscle biopsy, her husband reported that the patient was confused. Confusion progressed over 3 days, and she experienced episodes of urinary and fecal incontinence prompting admission to her local hospital. Results of screening blood tests and CT scan of the brain were reported as normal. She was transferred to our institution for further management. At the time of transfer, she was not oriented to time or place, had gait disturbance with distal weakness, and showed marked confabulation. It was feared that she had a progressive autoimmune condition affecting her central nervous system. Methylprednisone was commenced at 2 mg/kg i.v. dose (total of 170 mg) on the day of transfer. Brain MRI showed hyperintense white matter foci in both subcortical [enhancing on fluid-attenuated inversion recovery (FLAIR)] and periventricular areas (nonenhancing). There were ovoid lesions perpendicular to the ventricles and lesions involving the corpus callosum (Fig. 1). All lesions showed restricted diffusion. The findings were consistent with either demyelination or an ischemic process.

The methylprednisone dose was increased to 1 g per day, and further investigations were performed. Lumbar puncture revealed no evidence of viral, fungal, or mycobacterial infection. Cytology showed no malignant cells, and cerebrospinal fluid (CSF) protein (0.27 g/L) and glucose (4.4 mmol) were normal. Oligoclonal bands were detected in the CSF, with an IgG concentration of 0.033 g/L (albumin, 0.160 g/L; and IgG/albumin ratio, 0.208), but a similar pattern was seen in the serum, and a normal IgG index was detected. These results suggested a systemic immune response, rather than one originating in the central nervous system. A repeat brain MRI after 10 days of steroid treatment showed increased enhancement in the previously noted lesions and lesions involving the cortex, changes more suggestive of multiple infarctions and possibly a vascular process.

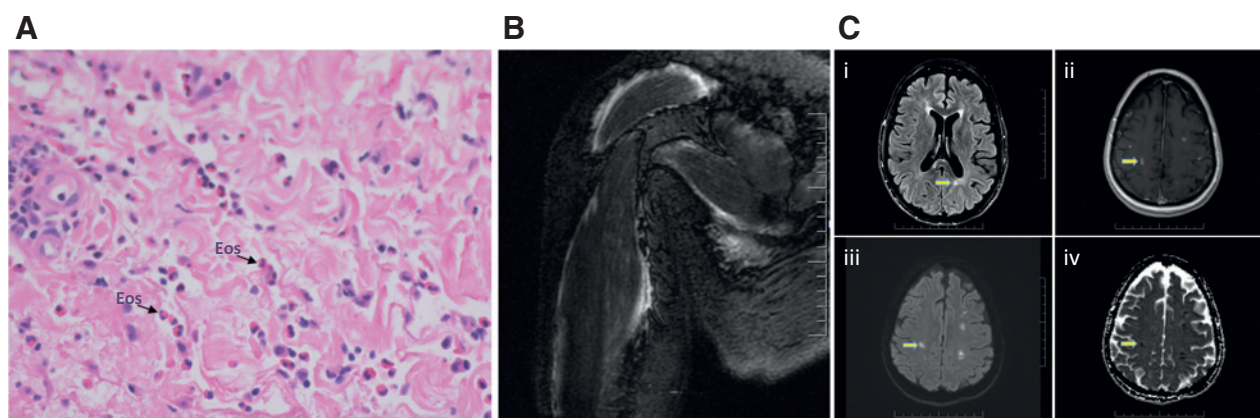


Figure 1.

A, full thickness muscle biopsy from the right upper arm demonstrating eosinophilic fasciitis. The dermis is infiltrated with a superficial and deep lympho-eosinophilic infiltrate. A denser infiltrate of eosinophils is seen in the fascia along with plasma cells and lymphocytes. These changes were mirrored in the subcutaneous tissue [eosinophils (Eos) are shown with arrows]. B, MRI of the right upper arm depicts marked fascial edema involving the deltoid, rotator cuff musculature, biceps, and triceps. This edema tracks in to the right chest wall musculature. C, axial MRI images of the brain during the acute presentation of confusion (arrows highlight changes described). i, T2/FLAIR sequence showing subcortical lesions involving the periventricular white matter and the splenium of the corpus callosum. Such changes are often seen in demyelination but may also be compatible with a vascular etiology. ii, axial T1-post gadolinium sequence showing multiple small scattered lesions throughout bilateral cerebral hemispheres. The superficial lesions enhance while the deep lesions do not. This picture focuses on the superficial lesions only. iii, axial diffusion sequence demonstrating several small lesions restricting diffusion in bilateral cerebral hemispheres, predominantly affecting the white matter, compatible with a vascular process. iv, apparent diffusion coefficient sequence showing decreased signal at the emplacement of the lesions, most commonly seen with lesions of vascular etiology.

Table 1. Blood and cerebrospinal fluid investigations of interest during management of late toxicity in our patient

Investigation	Eosinophil count	ESR (mm/h)	Creatinine kinase (IU/L)	LDH (U/L)	CSF protein/glucose(g/l)	CSF IgG/albumin/ratio (g/L)	CSF cytology/infection screen
4 weeks	0.8		44	257			
10 weeks	1.8	15	28	306			
12 weeks	5.24		47	431			
14 weeks	1.7			497			
14 weeks and 3 days					0.27/4.4	0.033/0.16/0.208	Negative/negative
14 weeks and 4 days	0.03			347			

NOTE: Normal ranges: eosinophil count $0.04-0.4 \times 10^9/l$, ESR 0-20, CK ≤ 149 , lactate dehydrogenase (LDH) 125-220, CSF protein 0.15-0.45, CSF glucose 2.2-4.4, CSF IgG 0.005-0.06, CSF albumin 0.134-0.237, IgG/albumin ratio ≤ 0.249 .

A steroid taper of 5 mg/week was initiated, starting with 60 mg of prednisone, and aspirin (81 mg; in view of the infarcts) was commenced. A subsequent transthoracic echocardiogram was normal, and CT angiography did not reveal large or medium vessel vasculitis or any evidence of intracranial hemorrhage. The eosinophil count was 1.7 on day of transfer to our institution and returned to normal 6 days later. Table 1 details results of serial blood investigations during the investigative workup. The confusion and fasciitis resolved within 20 days of transfer to our institution; weakness and deficits in proprioception and gait improved more slowly. At the time of this report, the patient was improving in active rehabilitation prior to discharge home. Mild contractures of the elbows to 10 degrees and the fingers of the right hand are present, her performance status is 1 (compared with a performance status of 0 at baseline).

Discussion and Conclusions

Eosinophilic fasciitis is a rare disorder of unknown etiology characterized by painful symmetrical swelling and thickening of the skin in the distal extremities and rarely the trunk and neck (7). Progression causing induration of the skin and fibrosis of fascia gives rise to contractures and, in extreme cases, restriction of the chest wall musculature; visceral involvement is usually absent. Prior to presentation, patients may have myalgia, weight loss, inflammatory polyarthritis, or a history of a change in medication or intense physical exercise preceding infection. There may be an underlying diagnosis of a hematologic disorder, solid tumor, or autoimmune disease. Full skin to muscle biopsy is required for diagnosis, with characteristic findings being an inflammatory infiltrate of lymphocytes ($CD8^+$ T cells predominate with macrophages) and/or eosinophils in the fascia but complete or relative sparing of the epidermis and dermis. Blood tests may not be informative: ESR is often normal or only mildly elevated. High-dose steroid treatment typically results in complete resolution in the majority of cases. Eosinophilic fasciitis is a distinct entity unrelated to eosinophilic vasculitis. However, there are reports of associated small vessel vasculitis with digital gangrene occurring in eosinophilic fasciitis, suggesting some overlap with connective tissue disorders, such as scleroderma (8, 9). Cerebral vasculitic changes on angiography have been described in a patient with eosinophilic fasciitis, causing a hemorrhagic stroke (10). We were unable to assign a definite diagnosis to the patient's neurologic disorder. Having ruled out a demyelinating process and embolism from the heart or large vessels, the clinical and radiologic findings were suggestive enough of cerebral vasculitis that we continued steroid treatment on which she had shown improve-

ment. It is possible that the initial eosinophilic fasciitis in our patient progressed to small vessel vasculitis of the brain.

Pembrolizumab has significant activity in metastatic melanoma. Responses often occur as early as the first assessment scan, with incremental decreases in tumor measurements thereafter. Late responses are rare (2, 3, 11, 12). In this patient, maximum response or CR was achieved after 13.8 months of treatment and has been durable to date. However, there is no defined optimal duration of treatment with pembrolizumab. The Keynote-001 phase I trial used an indefinite schedule (2-4), whereas the first-line Keynote-006 trial assesses a treatment schedule of 2 years (11).

Reported toxicity with pembrolizumab has been lower than with ipilimumab. The majority of adverse events have been grade 2 or lower, and reversible. The incidence of grade 3-5 toxicity across different cohorts in Keynote-001 (2-4, 13) and Keynote-006 (11) was 13%. These toxicities ranged from pneumonitis (<1%), fatigue (<1%), colitis (<1%-3%), diarrhea (<1%-3%), hypophysitis (<1%), hypothyroidism (<1%), nausea (<1%), and arthralgia (<1%). Rare toxicities in individual patients of type 1 diabetes (14) or myocarditis and cardiac failure (15) due to pembrolizumab have also been reported.

Our case is, to our knowledge, the first reported case of eosinophilic fasciitis with an antibody to PD-1. The timing of this side effect in our patient occurred after 18 months of treatment, during which no toxicity occurred. Eosinophilic fasciitis is an immune-related condition and, in this context, is an IrAE. Although we did not perform a biopsy of the patient's brain lesions or subject her to invasive 4-vessel angiography, these were possibly immune mediated as well. The rapid response to steroids is reassuring, although the patient has yet to make a full recovery.

The durability of pembrolizumab responses is unknown. Future trials must explore different schedules of treatment to determine the optimal treatment duration. Continued monitoring of patients on anti-PD-1 inhibitors will determine the risk of delayed toxicity, its severity, and reversibility.

Disclosure of Potential Conflicts of Interest

M.O. Butler has received honoraria from the speakers bureau of Bristol-Myers Squibb Canada and Merck Canada; and is a consultant/advisory board member for Bristol-Myers Squibb and Merck. D. Hogg is a consultant/advisory board member for Bristol-Myers Squibb, Merck, and Roche. No potential conflicts of interest were disclosed by the other authors.

Disclaimer

N. Al-Faraidy was not available to confirm coauthorship, but the corresponding author, D. Hogg, affirms that N. Al-Faraidy contributed to the article and thus confirms her coauthorship status.

Khoja et al.

Authors' Contributions

Conception and design: L. Khoja, A.S. Al-Habeeb, W. Mason, D. Hogg

Acquisition of data (provided animals, acquired and managed patients, provided facilities, etc.): L. Khoja, M. Chappell, L. MacMillan, A.S. Al-Habeeb, P. Rogalla, W. Mason, D. Hogg

Analysis and interpretation of data (e.g., statistical analysis, biostatistics, computational analysis): L. Khoja, M.O. Butler, W. Mason, A.M. Joshua

Writing, review, and/or revision of the manuscript: L. Khoja, C. Maurice, L. MacMillan, M.O. Butler, P. Rogalla, W. Mason, A.M. Joshua, D. Hogg

Administrative, technical, or material support (i.e., reporting or organizing data, constructing databases): L. Khoja, A.S. Al-Habeeb

Study supervision: W. Mason, D. Hogg

Other (provided patient data): M. Chappell

Grant Support

L. Khoja was supported by grants from the Canadian Institute of Health Research and the Guglietti Family Fellowship fund.

Received July 28, 2015; revised September 30, 2015; accepted October 14, 2015; published OnlineFirst January 28, 2016.

References

- Schadendorf D, Hodi FS, Robert C, Weber JS, Margolin K, Hamid O, et al. Pooled analysis of long-term survival data from phase II and phase III trials of ipilimumab in unresectable or metastatic melanoma. *J Clin Oncol* 2015;33:1889–95.
- Robert C, Ribas A, Wolchok JD, Hodi FS, Hamid O, Kefford R, et al. Anti-programmed-death-receptor-1 treatment with pembrolizumab in ipilimumab-refractory advanced melanoma: a randomised dose-comparison cohort of a phase 1 trial. *Lancet* 2014;384:1109–17.
- Hamid O, Robert C, Daud A, Hodi FS, Hwu WJ, Kefford R, et al. Safety and tumor responses with lambrolizumab (anti-PD-1) in melanoma. *N Engl J Med* 2013;369:134–44.
- Robert C, Joshua AM, Weber JS, Ribas A, Hodi FS, Kefford RF, et al. LBA34PEMBROLIZUMAB (PEMBRO; MK-3475) for advanced melanoma (MEL): randomized comparison of two dosing schedules. *Ann Oncol* 2014;25(suppl 4).
- Weber JS, D'Angelo SP, Minor D, Hodi FS, Gutzmer R, Neyns B, et al. Nivolumab versus chemotherapy in patients with advanced melanoma who progressed after anti-CTLA-4 treatment (CheckMate 037): a randomised, controlled, open-label, phase 3 trial. *Lancet Oncol* 2015;16:375–84.
- Weber JS, Antonia SJ, Topalian SL, Schadendorf D, Larkin JMG, Sznol M, et al. Safety profile of nivolumab (NIVO) in patients (pts) with advanced melanoma (MEL): A pooled analysis. *ASCO Meeting Abstracts* 2015;33(15_suppl):9018.
- Long H, Zhang G, Wang L, Lu Q. Eosinophilic skin diseases: a comprehensive review. *Clin Rev Allergy Immunol* 2015 Apr 16. [Epub ahead of print].
- Song YW, Kim HA, Song KY. Eosinophilic fasciitis with occlusive vasculitis and gangrene of the finger. *J Rheumatol* 1995;22:356–9.
- Magaro M, Altomonte L, Zoli A, Mirone L, Massi G, Federico F. Eosinophilic fasciitis associated with inflammatory neutrophilic vasculitis. *Br J Rheumatol* 1990;29:145–6.
- Cecchi PC, Caramaschi P, Pinna G, Schwarz A, Bricolo A. Haemorrhagic stroke and vasculitic-like cerebral angiography in a patient with eosinophilic fasciitis. Case report. *J Neurosurg Sci* 2006;50:119–22.
- Robert C, Schachter J, Long GV, Arance A, Grob JJ, Mortier L, et al. Pembrolizumab versus ipilimumab in advanced melanoma. *N Engl J Med* 2015;372:2521–32.
- Lyle MK, Lee JH, Menzies AM, Chan MM, Clements A, Carlino MS, et al. Lesion-specific patterns of response and progression with anti-PD-1 treatment in metastatic melanoma (MM). *ASCO Meeting Abstracts* 2014;32(15_suppl):9077.
- Ribas A, Hodi FS, Kefford R, Hamid O, Daud A, Wolchok JD, et al. Efficacy and safety of the anti-PD-1 monoclonal antibody MK-3475 in 411 patients (pts) with melanoma (MEL). *ASCO Meeting Abstracts* 2014;32(15_suppl):LBA9000.
- Martin-Liberal J, Furness AJ, Joshi K, Peggs KS, Quezada SA, Larkin J. Anti-programmed cell death-1 therapy and insulin-dependent diabetes: a case report. *Cancer Immunol Immunother* 2015;64:765–7.
- Laubli H, Balmelli C, Bossard M, Pfister O, Glatz K, Zippelius A. Acute heart failure due to autoimmune myocarditis under pembrolizumab treatment for metastatic melanoma. *J Immunother Cancer* 2015;3:11.

Cancer Immunology Research

Eosinophilic Fasciitis and Acute Encephalopathy Toxicity from Pembrolizumab Treatment of a Patient with Metastatic Melanoma

Leila Khoja, Catherine Maurice, MaryAnne Chappell, et al.

Cancer Immunol Res 2016;4:175-178. Published OnlineFirst January 28, 2016.

Updated version Access the most recent version of this article at:
doi:[10.1158/2326-6066.CIR-15-0186](https://doi.org/10.1158/2326-6066.CIR-15-0186)

Cited articles This article cites 13 articles, 1 of which you can access for free at:
<http://cancerimmunolres.aacrjournals.org/content/4/3/175.full#ref-list-1>

Citing articles This article has been cited by 10 HighWire-hosted articles. Access the articles at:
<http://cancerimmunolres.aacrjournals.org/content/4/3/175.full#related-urls>

E-mail alerts [Sign up to receive free email-alerts](#) related to this article or journal.

Reprints and Subscriptions To order reprints of this article or to subscribe to the journal, contact the AACR Publications Department at pubs@aacr.org.

Permissions To request permission to re-use all or part of this article, use this link
<http://cancerimmunolres.aacrjournals.org/content/4/3/175>.
Click on "Request Permissions" which will take you to the Copyright Clearance Center's (CCC) Rightslink site.